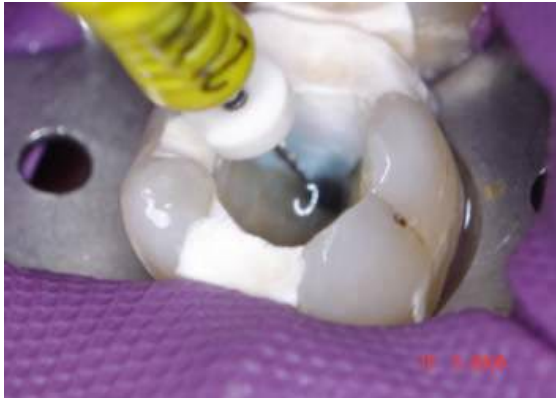
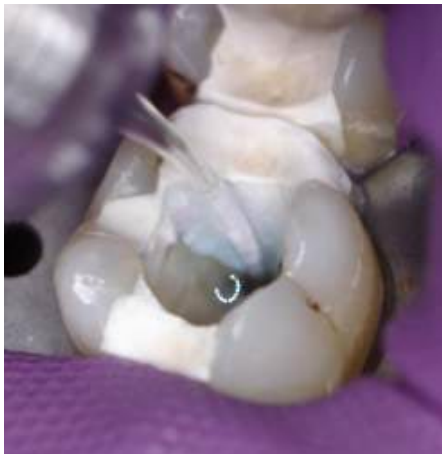
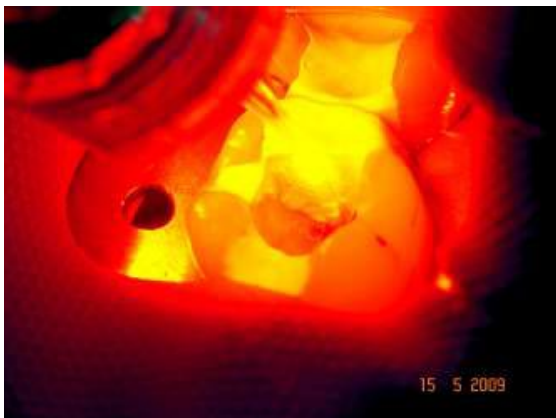
Case History 9 – PAD in Endodontics



1. 36 requiring root canal treatment. Pulp chamber is prepared and canals accessed. Each canal prepared in the conventional manner

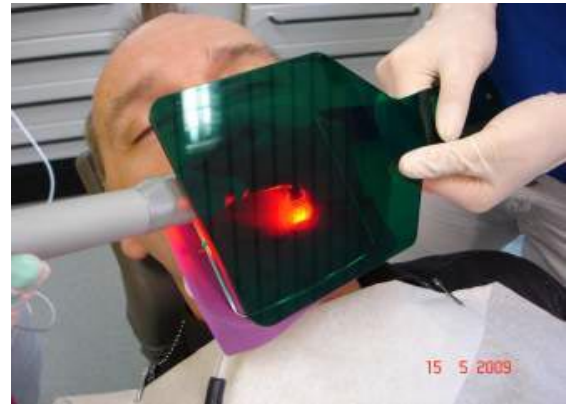


2. Once preparation is completed each canal is filled in turn with the photosensitizer. This is left in the canal for 60s while agitating with an endodontic instrument

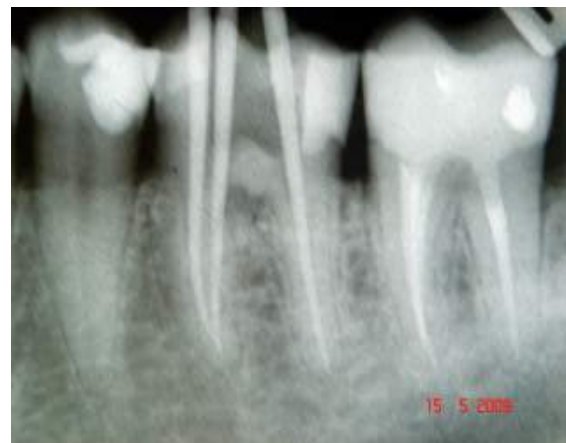

3. The endodontic tip is inserted into the canal and each canal illuminated for 120s

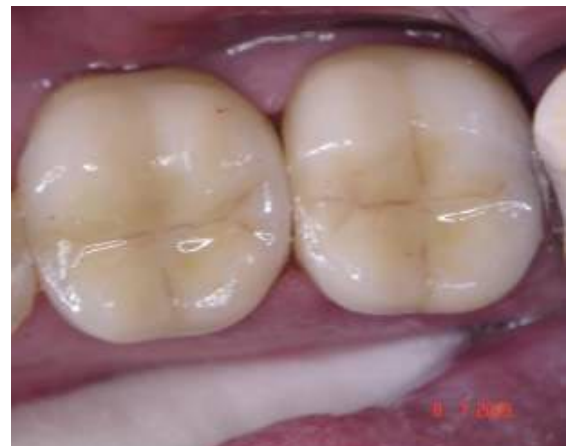Dr. Tobias Wieser



4. To protect the operator and nurse from the bright light a green filter screen may be placed over the oral cavity during this procedure



5. Pre-cementation radiograph shows the gutta percha points to be correctly positioned and these are cemented in place



6. The definitive restoration in place