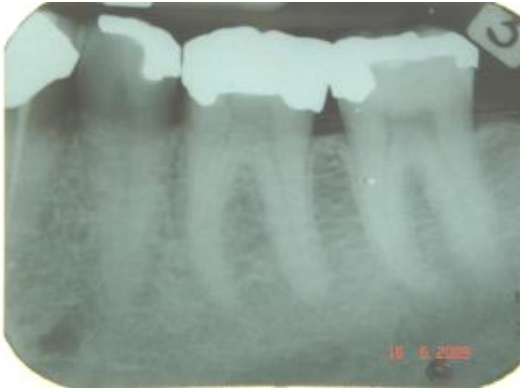
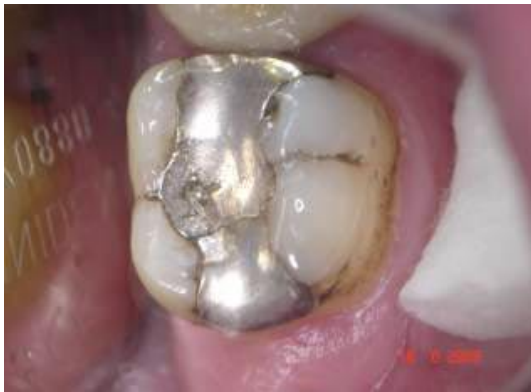

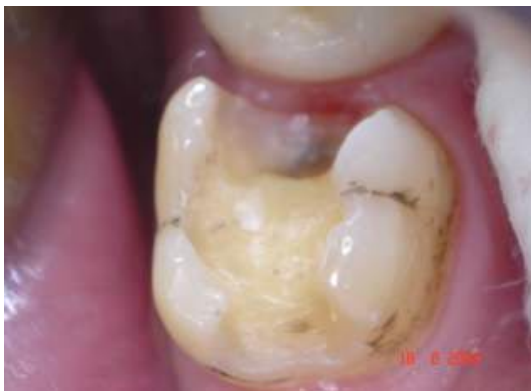Case History 7 -PAD in Caries



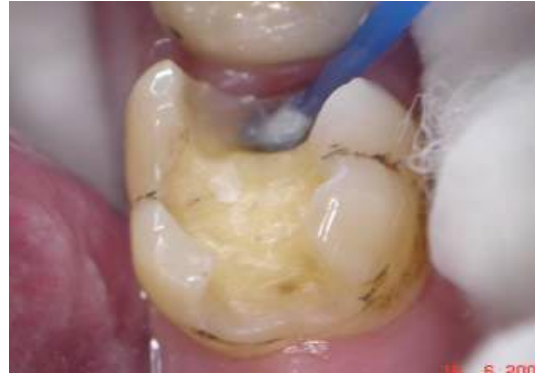1. 35, 36 and 37 showing large amalgam restoration in 37 with caries beneath the amalgam (mesially)




2. Restoration in 37 prior to removal. Note: crack across the occlusal surface and amalgam showing signs of creep



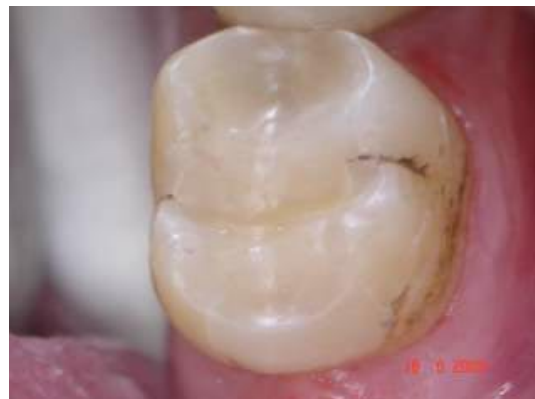3. Cavity after amalgam removal and cavity completion. Note extension of the cavity medially and deep mesial box



4. Due to depth and near exposure, cavity was treated using PAD. Photosensitiser is applied to the cavity and 60s contact time allowed



5. The light emitter is placed close to the site of the active caries and the cavity illuminated for 60s. At this point any remaining bacteria within the dentine will be killed



6. 37 with the final restoration in place. Note that there is no discolouration of the aesthetic restorative.

Dr Tobias Wieser