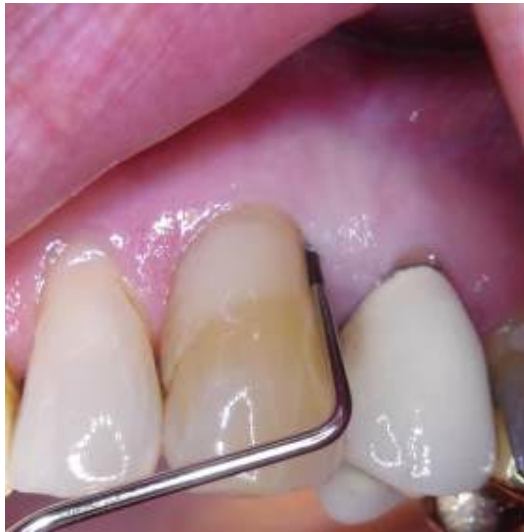

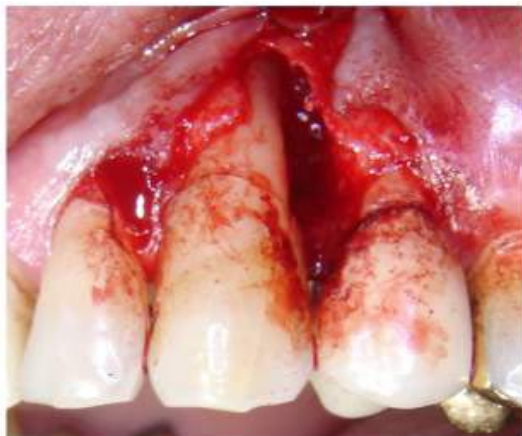Case History 4 - PAD Plus in Periodontics (2)

Dr Tobias Wieser

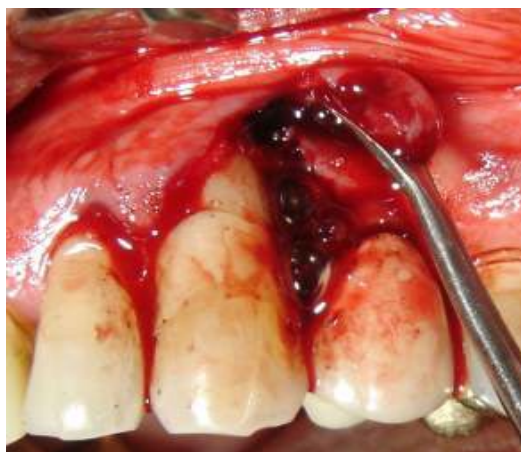Treatment of deep pocket using PAD in conjunction with surgery and direct curettage



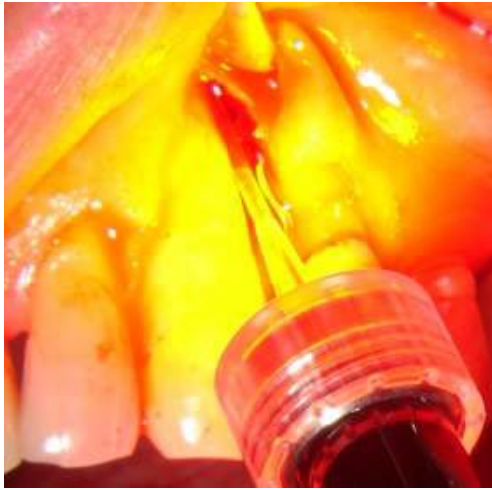Deep pocket on distal aspect of 23 approximately 8-9 mm deep



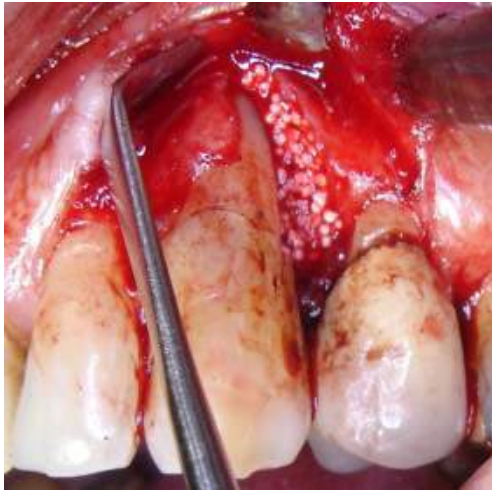
After raising flap the bony pocket is exposed and the extent of the lesion is visible



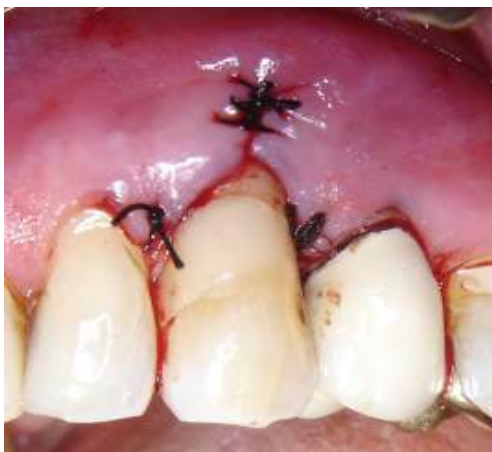The pocket is debrided using conventional hand instruments



After application of the photosensitiser for 60 seconds the periodontal tip is attached to the light guide and placed in the depth of the pocket. The light is activated for 60 seconds.



To facilitate healing the pocket is packed with bone regenerating material



The flap is repositioned and sutured in place